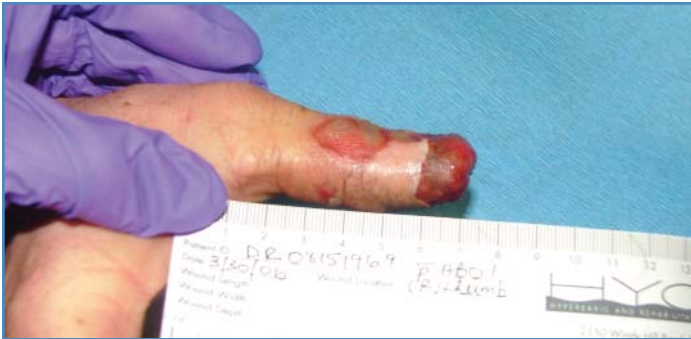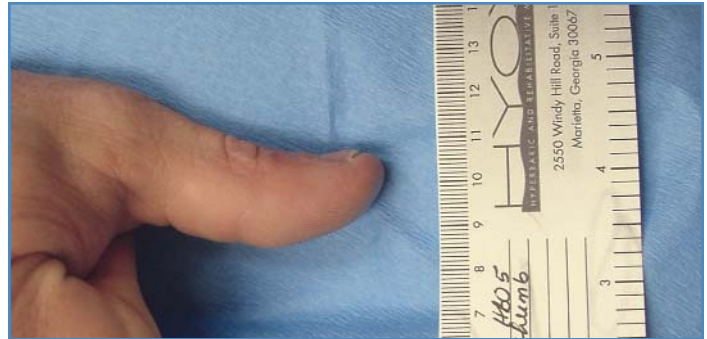


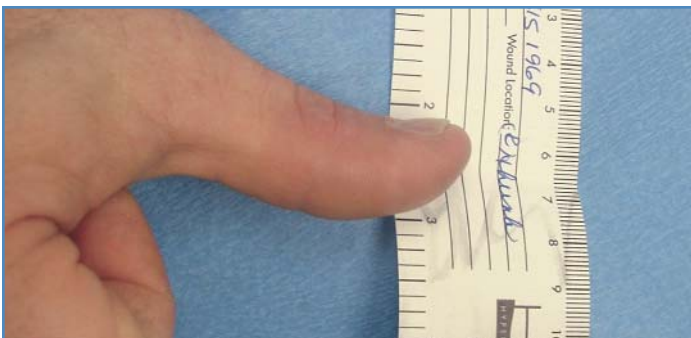Hyperbaric Oxygen Treatment for Crush Injury – Right Hand



Initial Visit



Treatment 5



Final Visit

This 36-year-old male was presented to HyOx with acute traumatic peripheral ischemia and crush injury to the right thumb and degloving from a belt sander accident at home. After debridement, soaking and X-rays at an urgent care center (which showed the distal phalanx was splintered), the patient was referred for hyperbaric oxygen. The patient participated in five hyperbaric treatments from 3/30/06 to 4/5/06. It was noted the patient had marked improvement even after the first treatment. He continued to improve with each treatment with salvage of the flap and increased granulation tissue on the distal thumb. He also regained sensation to sharp, dull and pain after starting hyperbarics. End Result: The patient experience complete healing and has full sensation. No grafting was required.