

Hyperbaric Oxygen Treatments for Chronic Wounds – Left Leg

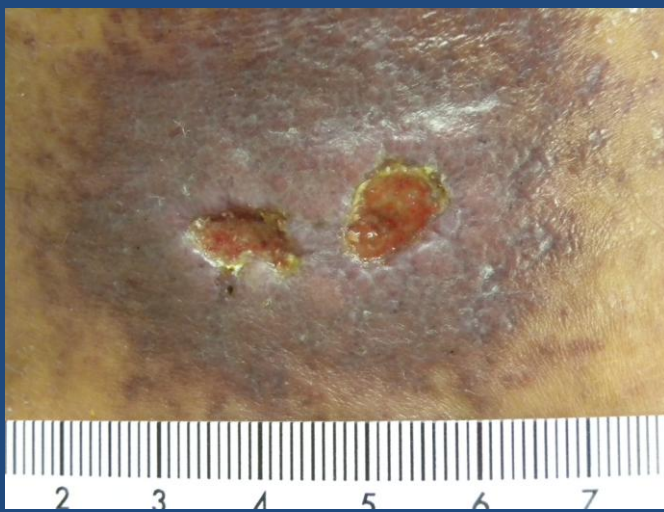


Figure 1: Initial Consult

9/29/10

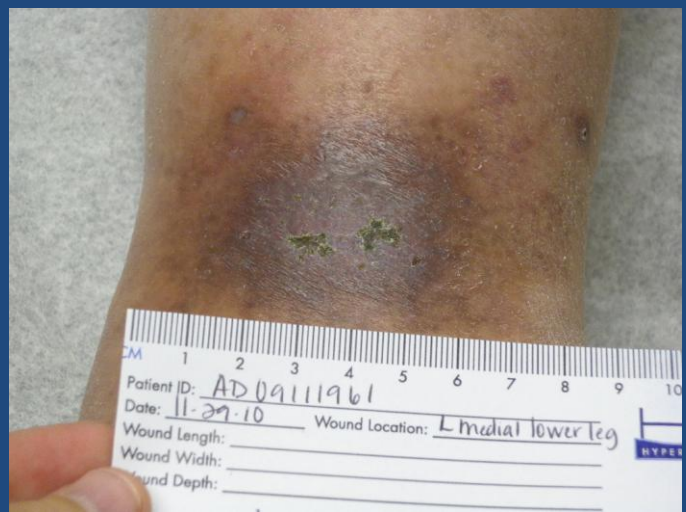

Figure 2: Treatment #13

11/29/10

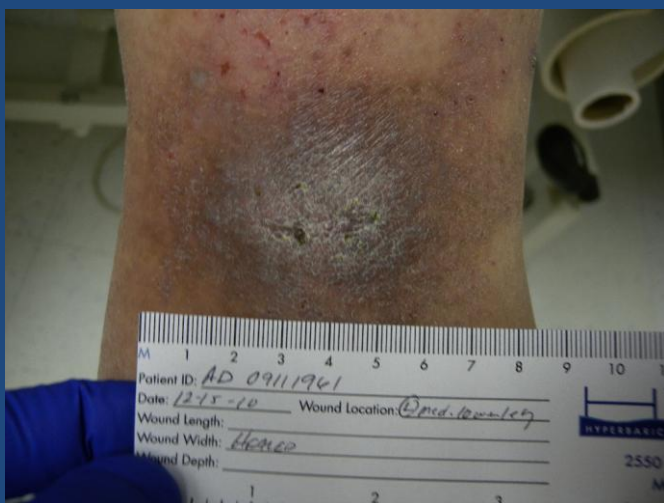

Figure 3: Treatment #20

12/15/10

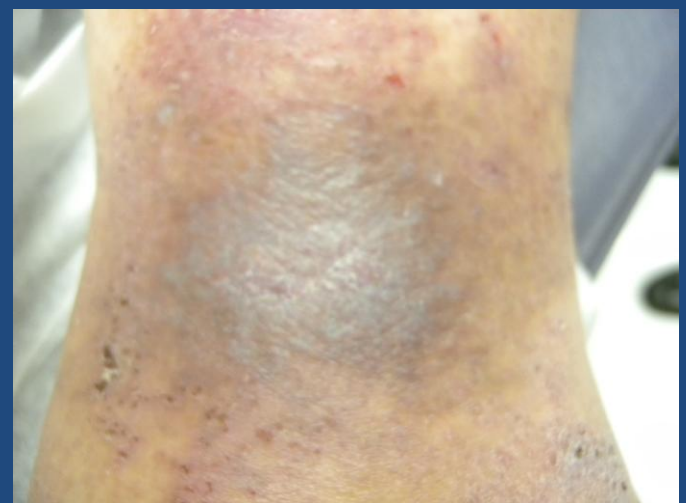

Figure 4: Follow-Up Visit

1/26/11

This 49-year-old male has a history of morbid obesity, Wegener's granulomatosis, left lower extremity DVT, and chronic venous insufficiency. He reports a left leg wound beginning over four months ago with a tear/abrasion while applying compression garments. At the site of a punch biopsy done six years ago, an enlarged hyperkeratotic growth resulted.

Result: With meticulous wound care, oral antibiotic therapy, wound debridement, vascular assessment studies, compression therapy, and 20 adjunctive hyperbaric oxygen therapy treatments, the patient's chronic left lower extremity wounds healed without further stasis and/or deterioration, thus minimizing further risk and complications.