

Hyperbaric Oxygen Treatments for Failure of Trans-Metatarsal Flap – Right Foot

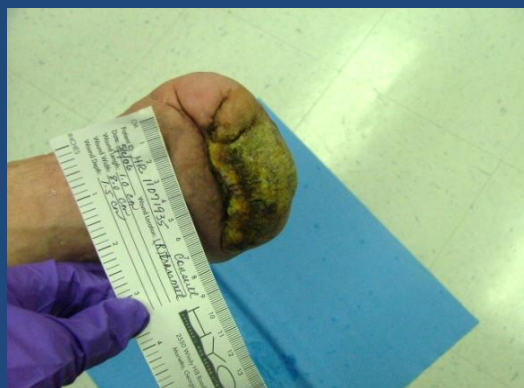


Figure 1: Initial Visit 5/2/06

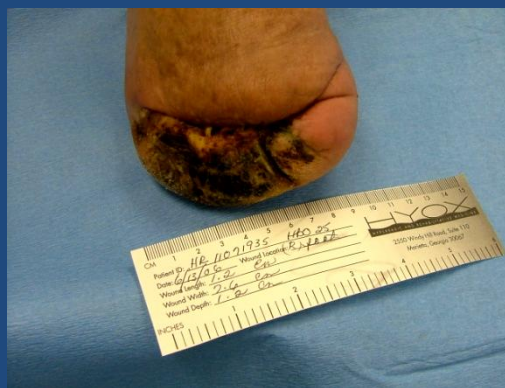

Figure 2: Treatment #25 6/13/06

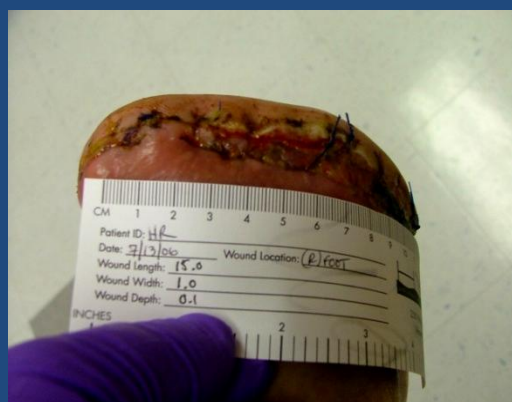

Figure 3: Treatment #42 7/13/06

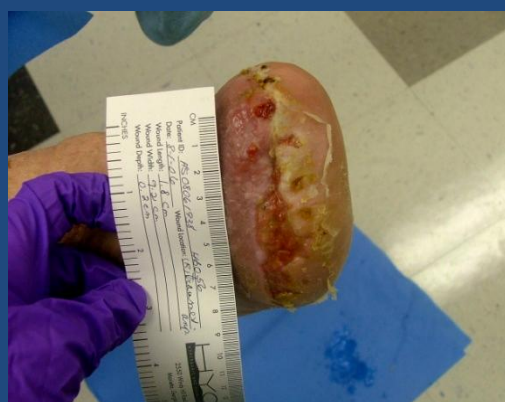

Figure 4: Treatment #54 8/1/06

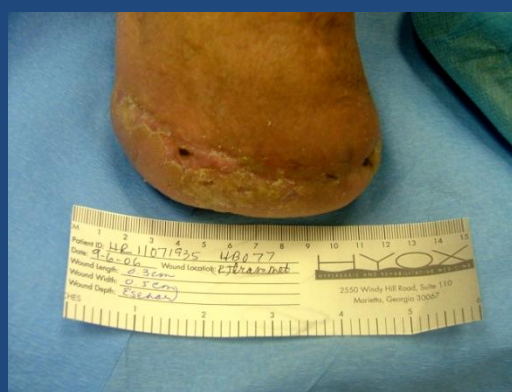

Figure 5: Treatment #77 9/6/06

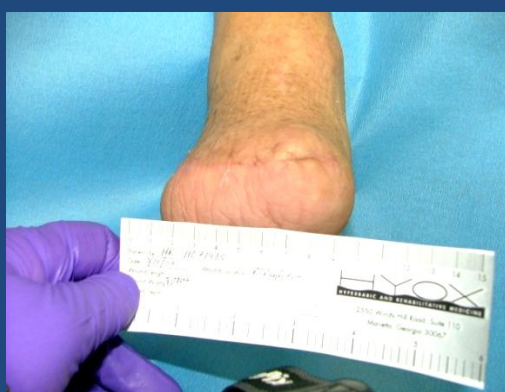

Figure 6: Follow-Up Visit 3/20/07

This 70 year-old male smoker had difficulty with his right foot after stepping on a wild Bradford pear tree. He initially lost his great toe, then his second toe. Three years later, he had a trans-metatarsal amputation. He had difficulty healing the distal wound and flap. The patient was referred to HyOx Medical Treatment Center and participated in 80 hyperbaric treatments with good compliance. During that time, he had debridement, surgical resection and closure of the wound.
Result: Healing.