

Hyperbaric Oxygen Treatments for Non-Healing Wagner Grade III Diabetic Ulcer – Left Foot

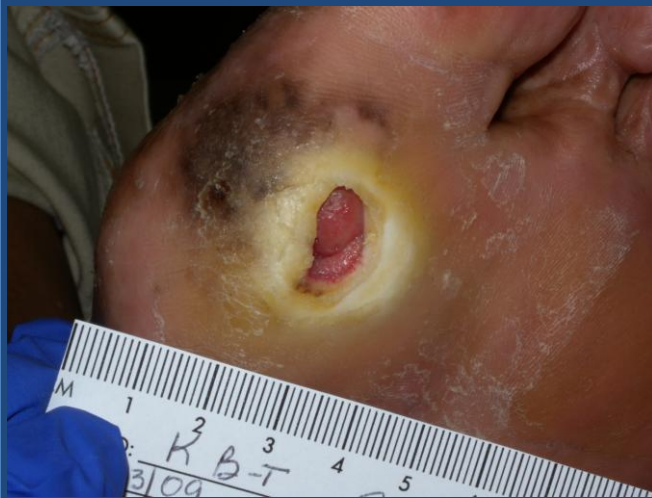

Figure 1: Initial Consult

11/13/09

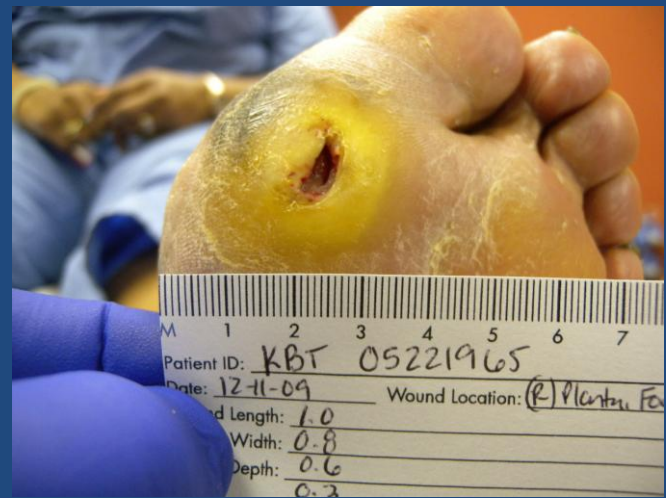

Figure 2: Treatment #7

12/11/09

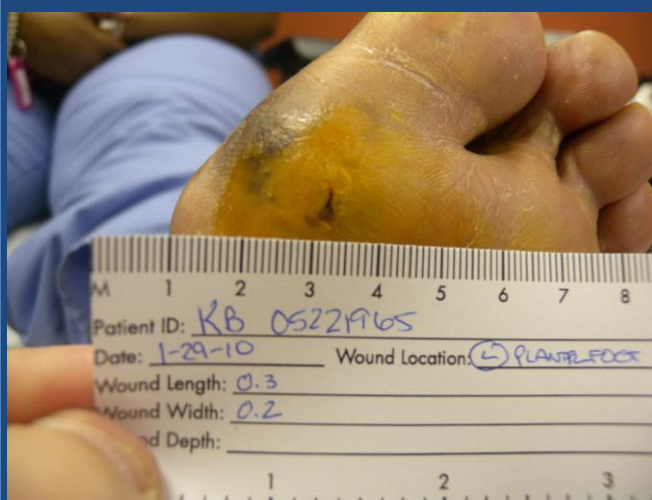


Figure 3: Treatment #27

1/29/10

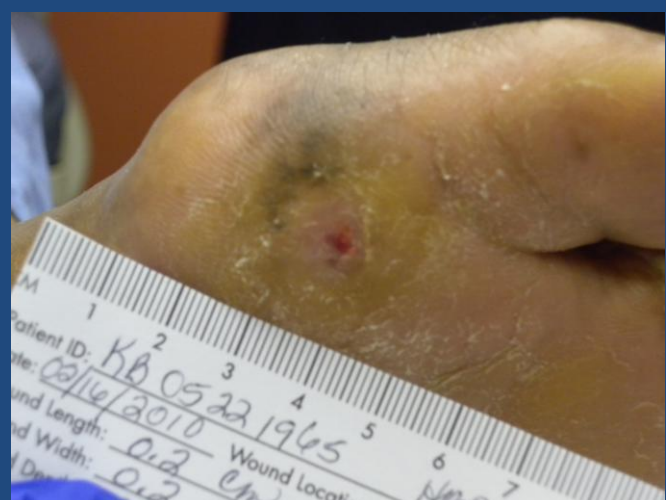

Figure 4: Treatment #34 – Final Visit

2/16/10

This 44-year-old female with a 12-year history of diabetes mellitus, hypertension, and status post ovarian cancer with hysterectomy and bilateral oophorectomy developed a non-healing Wagner grade III diabetic ulcer of the left first metatarsal plantar area. After more than eight months of unsuccessful conservative measures including offloading the foot, topical antibiotics and wound care; the patient was referred to HyOx Medical Treatment Center. The patient participated in 39 hyperbaric oxygen therapy treatments.

Result: The patient experienced significant wound improvement with wound debridements, hyperbaric oxygen therapy and offloading – resulting in healing.