

## Hyperbaric Oxygen Treatments for Soft Tissue Radiation Necrosis – Neck

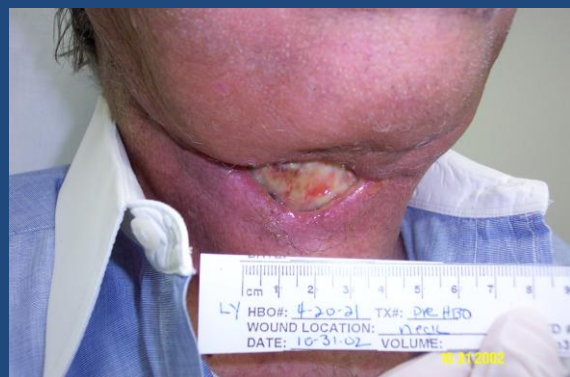

Figure 1: Initial Visit

10/31/02

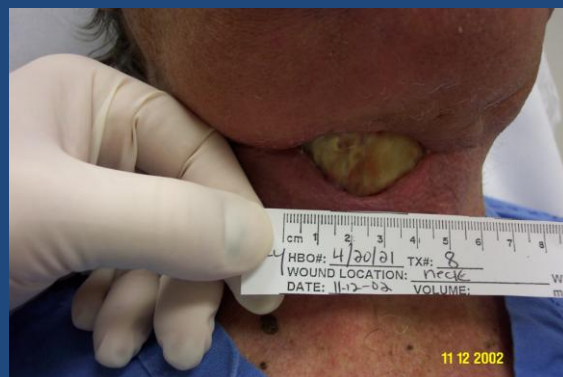


Figure 2: Treatment #8

11/12/02

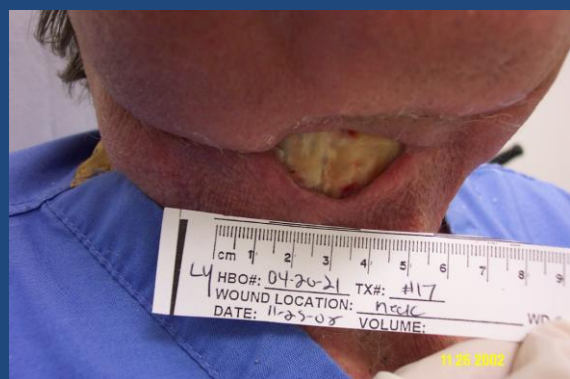

Figure 3: Treatment #17

11/25/02

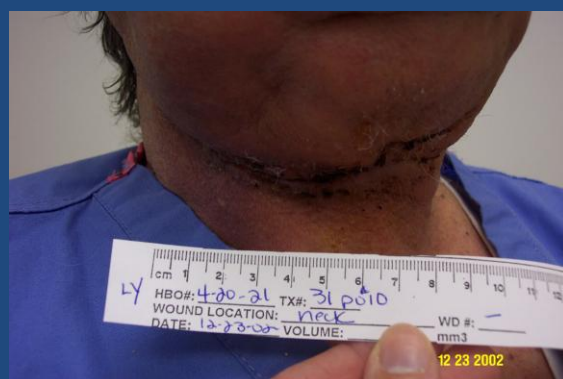

Figure 4: Treatment #31 – (#10 Post Op)

12/23/02

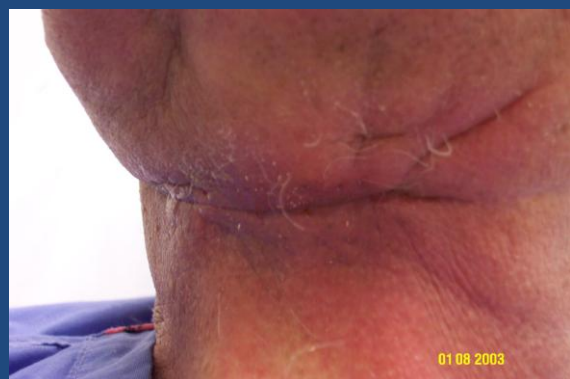

Figure 5: Treatment #42 – (#20 Post Op)

1/8/03

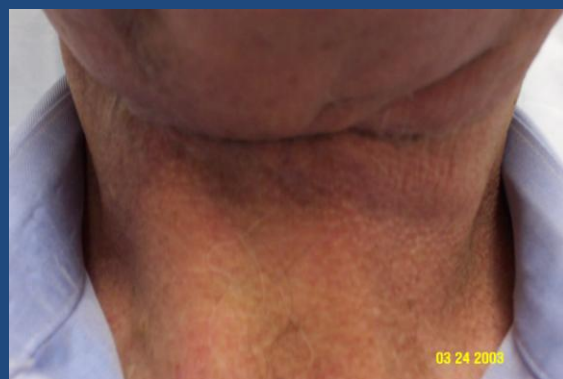

Figure 6: Follow-Up Visit - Final

3/24/03

This 81-year-old male was referred to HyOx Medical Treatment Center with soft tissue radiation necrosis of the anterior neck status post squamous cell carcinoma of the right tongue base. After his cancer diagnosis, the patient underwent a direct laryngoscopy and biopsy followed by radiation treatment. Although the patient had a right selective neck dissection, medial level 2, 3, 4 direct laryngoscopy and biopsy which was negative for squamous cell carcinoma, the patient continued to have difficulty with the area and began pre-op hyperbaric oxygen treatments (22) prior to neck closure and 28 post-op. **Result:** Following treatment, the patient showed good closure and no drainage. He can now eat and swallow without difficulty.