

Hyperbaric Oxygen Treatments for Soft Tissue Radionecrosis – Left Breast

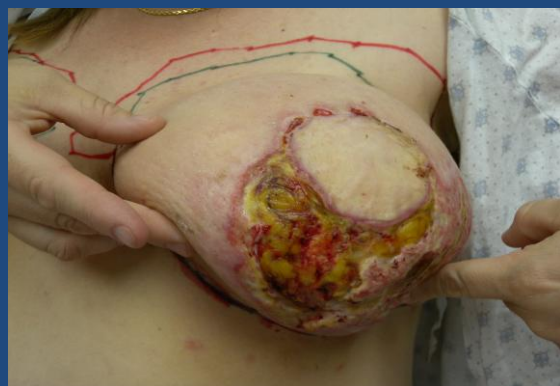

Figure 1: Initial Visit

4/27/10

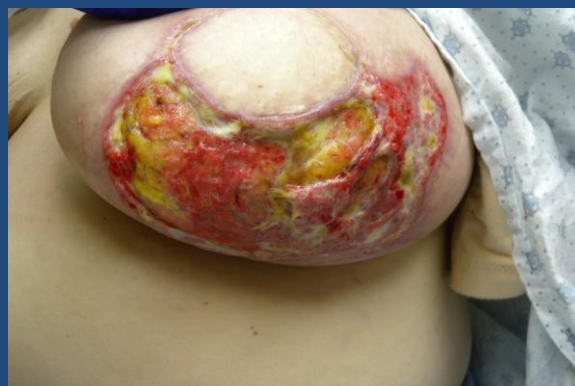

Figure 2: Treatment #7

5/7/10

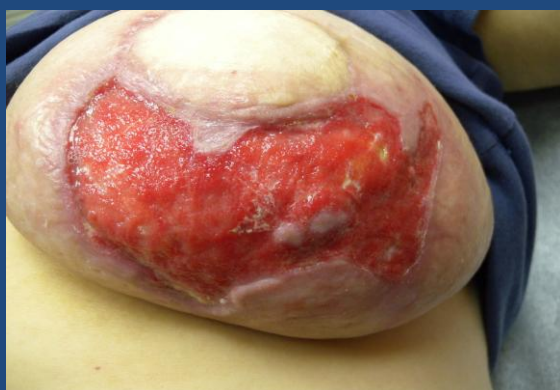

Figure 3: Treatment #27

6/2/10

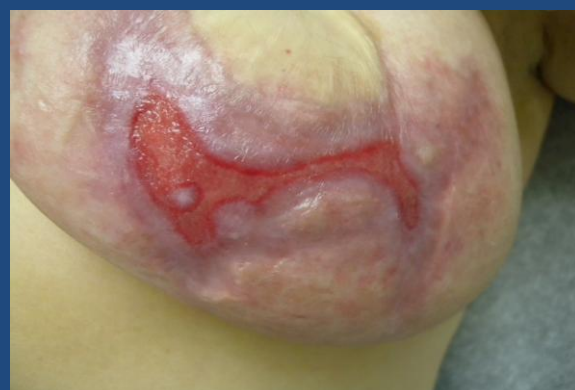

Figure 4: Treatment #38

6/24/10

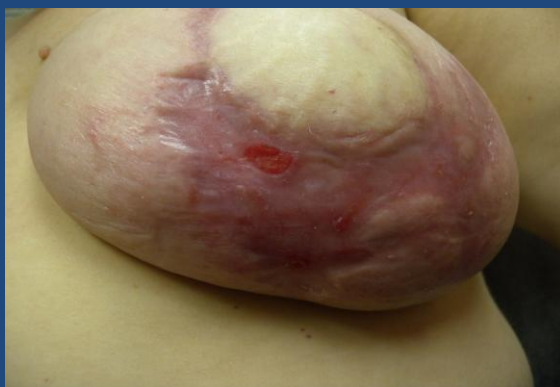

Figure 5: Treatment #45

7/8/10

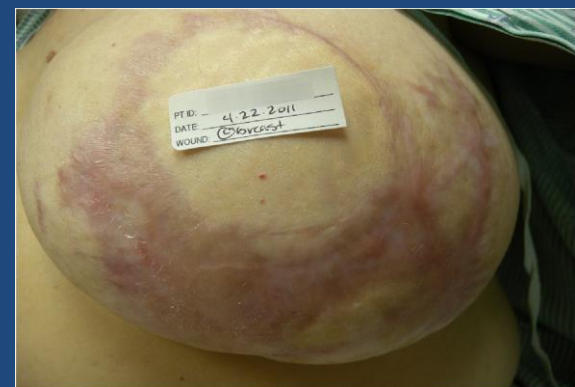


Figure 6: Final Follow-Up Visit

4/22/11

The patient, a 39-year old female, was diagnosed with high-risk breast carcinoma and elected to undergo bilateral mastectomies with reconstruction. Because of previous breast reduction surgery at age 16 and scar revision, she required a transverse rectus abdominis myocutaneous (TRAM) flap. Post surgery, she was noted to have blisters and necrosis of the skin. She was referred to HyOx Medical Treatment Center to heal her breast wounds. The patient participated in 52 hyperbaric oxygen treatments from 4/28/2010 to 7/30/2010.

Result: Healing and pain resolution.

NW Atlanta 2550 Windy Hill Road • Suite 110 • Marietta, Georgia 30067 • Phone 678.303.3200 • Fax 678.303.3205
Gwinnett 500 Medical Center Boulevard • Suite 170 • Lawrenceville, Georgia 30046 • Phone 678.672.1640 • Fax 678.672.1647