

## Hyperbaric Oxygen Treatments for Wagner Grade III Diabetic Ulcer – Right Foot

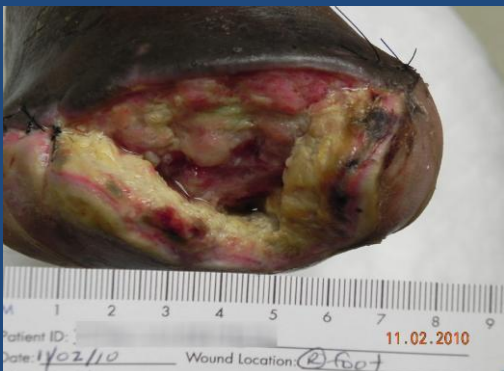

Figure 1: Initial Evaluation

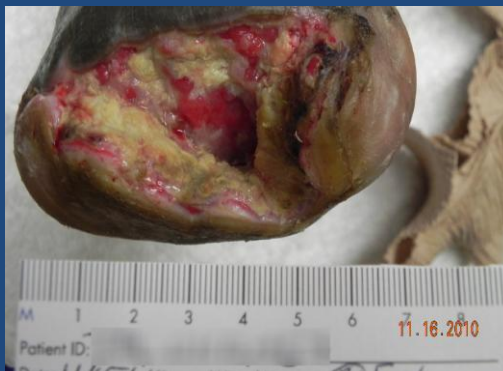

Figure 2: Treatment #8

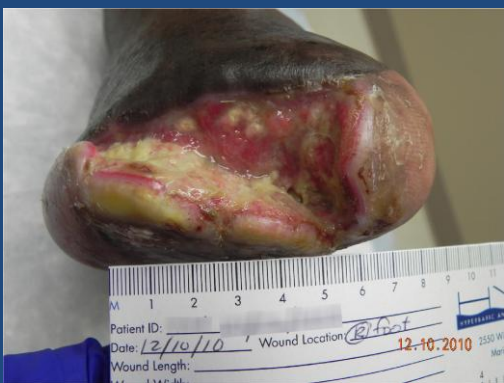

Figure 3: Treatment #25

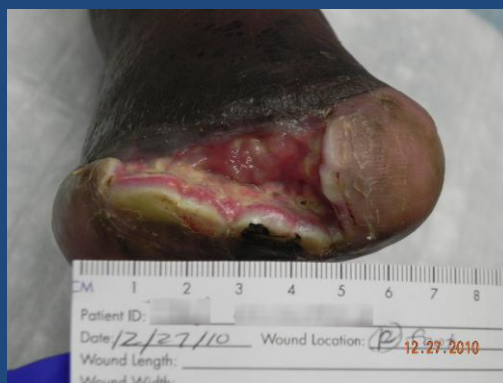

Figure 4: Treatment #34

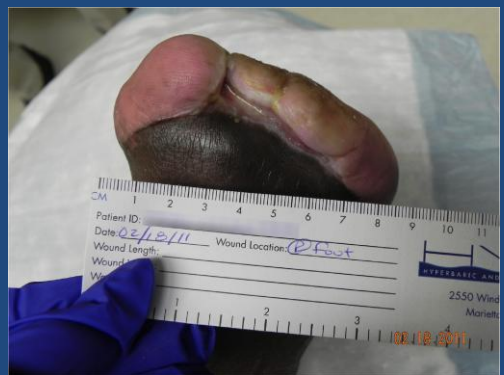

Figure 5: Treatment #60

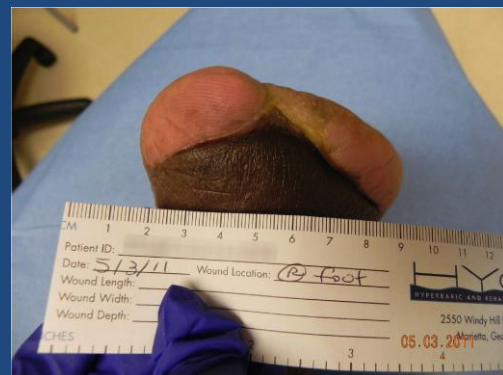


Figure 6: Follow-Up Visit

This 57-year-old male with a history of diabetes mellitus, end-stage renal disease on hemodialysis and vascular disease accidentally bumped his toe while walking. Two months later, the patient was admitted to the hospital with gangrenous changes and ensuing cellulitis. He underwent amputation of the right second and third toes, along with vascular assessment that showed severe bilateral tibioperoneal vascular disease and multiple wound infections. The wound showed a deep tunnel with pale granulation tissue. Adjunctive hyperbaric oxygen therapy was consulted at HyOx Medical Treatment Center in order to facilitate healing in this chronic diabetic foot ulcer. The patient participated in 60 hyperbaric oxygen treatments.

**Result:** Healing